

Dorso-Lateral Wedge correction osteotomy: Is this the way forward?

Viraj U Shingade¹

Abstract

In the present era of more and more advancements, when we are talking about mini invasive procedures, developing countries are still facing the major burden of neglected clubfoot deformities; where children present to orthopaedic surgeon at 5-18 years of age, not treated in the past. The orthopaedic surgeon to whom they present is in great dilemma about how to treat these cases. Majority of children cannot afford surgical procedures like Ilizarov which need expensive implants, and frequent visits to the specialised centres. Patients usually ask for one-time procedure which will give them the best chance of cure since they are brought for the treatment by charitable agencies or social workers. Dilemma in choosing correct method of treatment for these neglected or relapsed feet led to the evolution of a new single-staged, simpler and effective technique of dorso-lateral wedge corrective osteotomy. The procedure has been extensively studied in neglected as well as relapsed cases of club feet with long term follow up of more than 10 years. This review briefly describes the technical details of the procedure.

Keywords: Clubfoot, Club feet, Neglected, Relapsed, Osteotomy, Ponseti.

Introduction

The Need for new surgical technique: In the present era of more and more advancements, when we are talking about mini invasive procedures, developing countries are still facing the major burden of neglected clubfoot deformities; where children present to orthopaedic surgeon at 5-18 years of age, not treated in the past. These children walk on dorsum or dorso-lateral aspect of foot (Figure 1). They cannot use normal shoe-wear and are prone for injuries while playing games and walking long distances. They get repeated wounds at callosities, formed over dorsum of foot. They also have difficulty in squatting, which is the commonest position, used for day-to-day activities including toileting. Social stigma of having reversed feet is an important factor as such children are avoided by friends and girls experience problems in getting married.

The orthopaedic surgeon to whom they present is in great dilemma about how to treat these cases. Majority of children cannot afford surgical procedures like Ilizarov[1]

which need expensive implants, and frequent visits to the specialised centres. Patients usually ask for one-time procedure which will give them the best chance of cure since they are brought for the treatment by charitable agencies or social workers.

Extensive soft tissue releases in these cases, pose problems of skin approximation, wound healing and scarring[1, 2, 3]. Conventional bony procedures cannot fully correct these severe deformities and combination of multiple procedures is required[1,2,3,4,5,6]. Triple arthrodesis[5] is associated with stiffness and ankle arthritis. Ponseti's method for managing neglected cases have problems of compliance, frequent visits for plastering, expenses involved and subsequent need of osteotomies[7,8,9] to get complete correction.

Dilemma in choosing correct method of treatment for these neglected or relapsed feet due to above reasons led to the evolution of a new single-staged, simpler and effective technique of dorso-lateral wedge corrective osteotomy. The aim was not to obtain a

n o r m a l anatomical foot; but to obtain a foot which is more or less plantigrade and able to fit shoes. A longitudinal

follow up study was conducted by our institute to measure the outcome of this procedure in neglected as well as relapsed clubfoot deformities. The study was published [10] in the year 2012 with good follow up of cases and in fact now we have follow up more than 10 years of majority of our cases. Subsequently we found that the procedure was equally useful for neglected and relapsed cases of clubfoot associated with myelomeningocele and it was published[11] in the year 2014.

Operative Technique

The details of the operative technique are described in the published article in Journal Current Orthopaedic Practice [10] in the year 2012. The technique in brief is as follows: Under epidural anesthesia, the patient is placed supine; after painting and draping, the tourniquet is inflated. For correction of the cavus deformity, a percutaneous plantar fasciotomy is done (Figure 2A) from the medial aspect of the sole. The foot is then stretched manually to confirm complete release of plantar fascia. To correct the equinus, percutaneous Achilles complete transverse tenotomy (Figure 2B) is done and foot is stretched (dorsiflexed) manually. The Achilles tenotomy unlocks the heel, correcting equinus as well as heel varus. In rare cases of relapsed deformity if equinus is not corrected completely, the posterior ankle capsular release can be done through same incision. Attention is then directed to the dorsal closing wedge osteotomy. An elliptical skin incision is made on the dorso-

¹ Children Orthopaedic Care Institute and Pravira Hospital Daya chambers, Wardha road, Nagpur, Maharashtra.

Address of Correspondence

Dr Viraj U Shingade

Children Orthopaedic Care Institute and Pravira Hospital Daya chambers, Beside Haldiram Building, Ajani square, Wardha road, Nagpur, Maharashtra-440015.

Email: virajshingade@rediffmail.com



Dr Viraj U Shingade

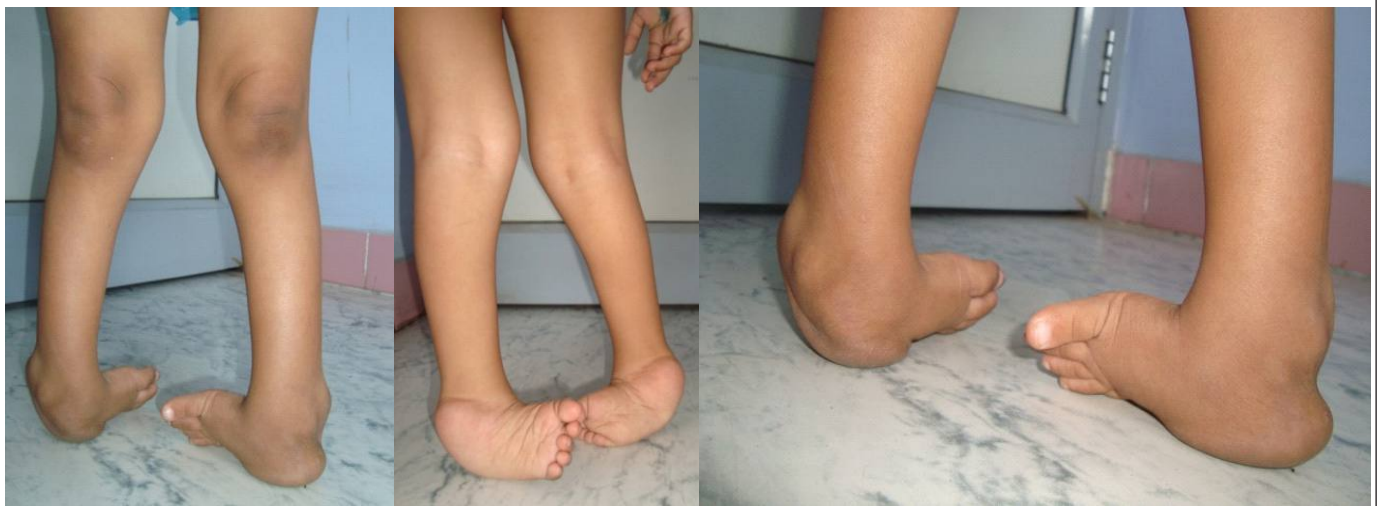

Figure 1: Six year girl with bilateral neglected clubfeet. These feet are prone for injuries at callosities formed at dorsum of feet.

lateral aspect at the apex of the deformed foot (Figure 2C). The incision extends from the lateral border of the foot to just short of the medial border. The elliptical skin and preformed bursa are excised. All dorsal musculature is separated and preserved with a periosteal elevator and chisel and then retracted. The dorsal neurovascular bundles are protected. The osteotomy is marked with an osteotome at the apex of the deformed foot. The wedge should be wider dorsally (1-2 cm) and taper towards the sole (Figure 2D). The amount of bony wedge required depends on the severity of the deformity. A rough clinical guide that can be used is that children who walk on the lateral border of the foot usually do not require more than 1-1.5cm of

wedge; those who walk on the dorsum of foot may need more than 1.5cm of wedge. One can always remove additional bone if the correction is found to be inadequate. This also prevents the over-correction. The bones included in wedge are cuboid and all three cuneiforms. Occasionally, the navicular or distal calcaneus or base of the metatarsals may require osteotomy, depending on the severity of the deformity. Occasionally impingement of the navicular against the head of the talus occurs, not allowing full correction of the deformity, even with cuboid and cuneiform osteotomy. In those patients, naviculectomy should be done, and sometimes an additional terminal portion of the talar head may need to be excised, taking

care not to disturb the subtalar joint. After wedge removal, care is taken to remove cartilage from the osteotomy bed and approximating edges to prevent nonunion and pseudarthrosis. No attempt is made to touch the subtalar joint. The deformity is then corrected by closing the space manually by everting and dorsiflexing the foot and by approximating the bony surfaces, as if closing an open book (Figures 2E and F). The forefoot is stabilized to the hindfoot with three Kirschner-wires passed from the metatarsals to the calcaneus (Figure 2G). Cancellous bone from the resected wedge is grafted at the osteotomy site. No attempt is made to look for radiographic correction because judgement is clinical. The wound is

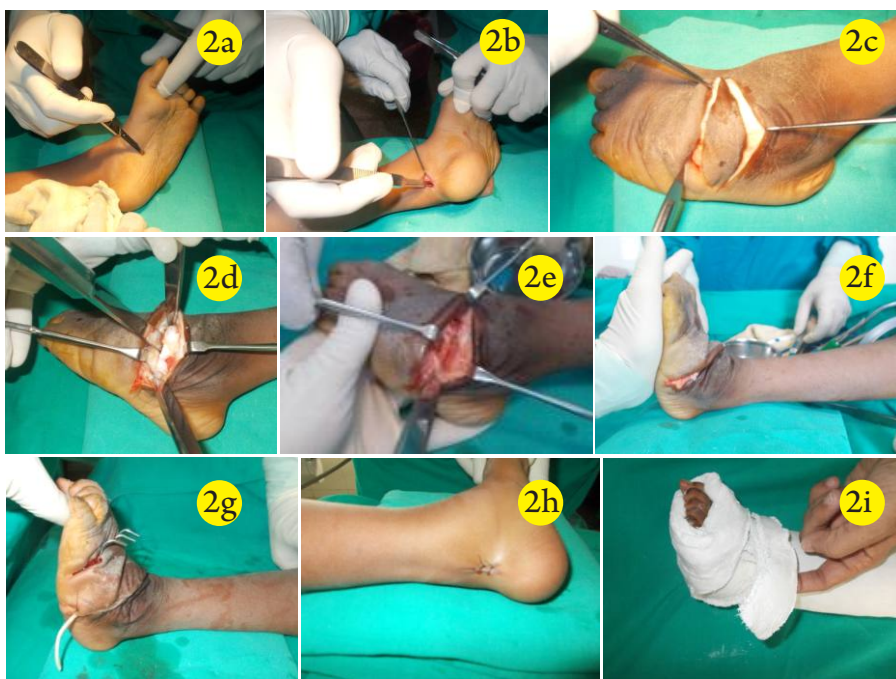


Figure 2A: Correction of cavus by percutaneous plantar fasciotomy

Figure 2B: Correction of equinus by percutaneous tendo-achilles tenotomy. In rare cases of relapsed deformity if equinus is not corrected completely, the posterior ankle capsular release can be done through same incision

Figure 2C: An elliptical skin incision placed dorso-laterally at apex of deformity.

Figure 2D: After preserving dorsal structures, osteotomy is marked with osteotome, at apex of the deformed foot. The wedge is wider dorsally (1 to 2 cm) and tapers towards sole.

Figure 2E: After removal of wedge deformity is corrected by closing space manually by everting and dorsiflexing the foot.

Figure 2F: Bony surfaces approximated and the deformity is completely corrected

Figure 2G: Stabilization of forefoot to hind-foot with three k-wires. A rubber drain in situ.

Figure 2H: View from back -complete correction of equinus as well-as heel-varus.

Figure 2I: Plaster-window made for wound check.

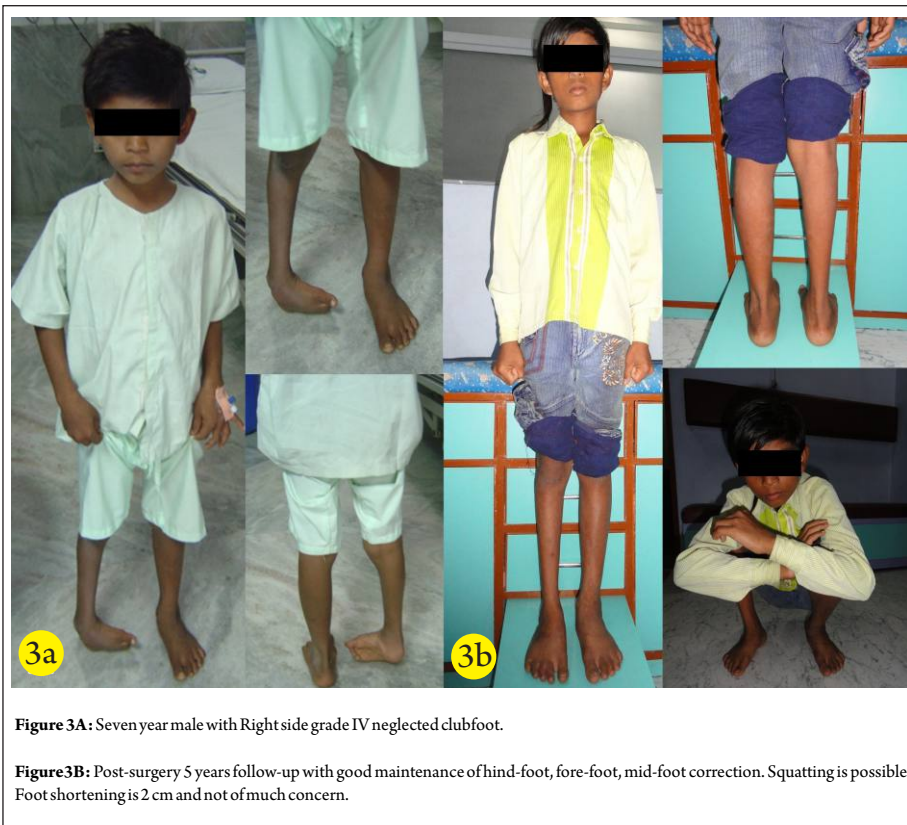

Figure 3A: Seven year male with Rightside grade IV neglected clubfoot.

Figure 3B: Post-surgery 5 years follow-up with good maintenance of hind-foot, fore-foot, mid-foot correction. Squatting is possible. Foot shortening is 2 cm and not of much concern.

closed after placing a drain (Figure 2G) and the tourniquet is deflated. An above-knee cast was applied. A window was made in the cast (Figure 2I), and the limb was kept elevated on pillows.

Three days of intravenous antibiotics are given along with an epidural for pain relief. On the third postoperative day, the wound is inspected through the window in the cast (Figure 2I). Hematoma, if present, should be removed along with the drain. Patients are discharged on the fourth postoperative day and non-weight bearing is advised for 6 weeks. After 6 weeks, the Kirschner-wires and cast are removed, and a plastic molded ankle-foot orthosis is applied to be worn for 6 months. Squatting is encouraged at home.

The foot deformities were graded according to classification system described by Dimeglio [12] and the results of the surgical procedure were studied extensively using evaluation system described by International Clubfoot Studygroup and Bensahel [13].

Discussion

Here we are not discussing about Dimeglio grade I or II deformities. We are discussing the neglected cases who have Dimeglio-grade III/IV deformities and who have come for the treatment at 5 yrs of age or later. Also we are discussing about patients with relapsed

clubfeet in developing countries who present late to the hospital and may have been operated on at hospitals where no experts were available. Hence, at the time of presentation, they usually have severe (Dimeglio-grade III/IV) deformities that cannot be corrected with conventional procedures such as those described by Dwyer or Dillwyn Evans alone, and a combination of procedures [14,15,16] is required.

With the described technique, excellent and good results were achieved in 89.6% feet at our centre; indicating that the technique is effective and extremely useful in both relapsed as well as neglected clubfeet (Figure 3 and 4). When we compared the results of neglected feet and relapsed feet we found that the results were better in neglected feet. The lower proportion of excellent and good results in relapsed feet compared with neglected feet could be from scarring of previous surgeries with resultant stiffness at the ankle, subtalar, or mid tarsal joints. This was consistent [16,17,18] with other studies. We also found that the results were better in younger (<10 years) children due to less bony incongruity and better ability to remodel. Bones in these feet are so deformed that they cannot achieve normal radiographic relationships. Our results were independent of radiographic findings and were consistent

with other [18,19] studies. Only one child with poor results (bilateral relapsed feet) had complete correction of the deformity intraoperatively but was lost to follow-up for 59 months. The patient neither performed squatting exercises nor used splints, leading to recurrence. This suggests that squatting has an important role to play. In spite of poor results, he maintained good function.

No feet (including those with poor results) had clinical or radiographic evidence of arthritis at the ankle or any other joint in last 10 years of follow-up. A possible reason could be that our procedure preserves the subtalar joint. This is an advantage over tripleS arthrodesis.

Patients usually have foot discomfort and plantar pain during the initial few months after cast removal. This is due to sensitivity of the sole and disuse osteoporosis of the calcaneus and metatarsals. None of the patients complained pain during follow-up, which might be attributed to good fusion at the osteotomy site with the use of cancellous grafting.

Clubfoot is a three-dimensional deformity, with a contracted tendo-Achilles being the main deforming force. Achilles tenotomy unlocks the heel and corrects equines and heel varus. No separate procedure or calcaneal osteotomy is necessary for varus correction (Figures 2 H).

With the described technique one can achieve good correction of all components intra-operatively (Figures 2 G, H) and can have varus-valgus movements on the table. Meticulous preservation of dorsal structures preserves function and prevents wound complications.

In bilateral cases, we advise surgery on both feet under a single anesthesia; which reduces the rehabilitation time, saves resources, and provides a unique opportunity for correction. This single-stage surgical procedure is easy, safe, and reproducible, and it can be performed with basic orthopaedic instruments.

There are no rigid criteria about specific bones to be osteotomized. If the surgeon performs an osteotomy at the apex of a deformed foot and takes out a wedge dorsally, tapering towards the sole, no error can occur.

There is no risk of neurovascular damage. By removing a dorsal wedge, tension in the system is released. Problems of medial scarring and wound breakdown are avoided because the technique is percutaneous

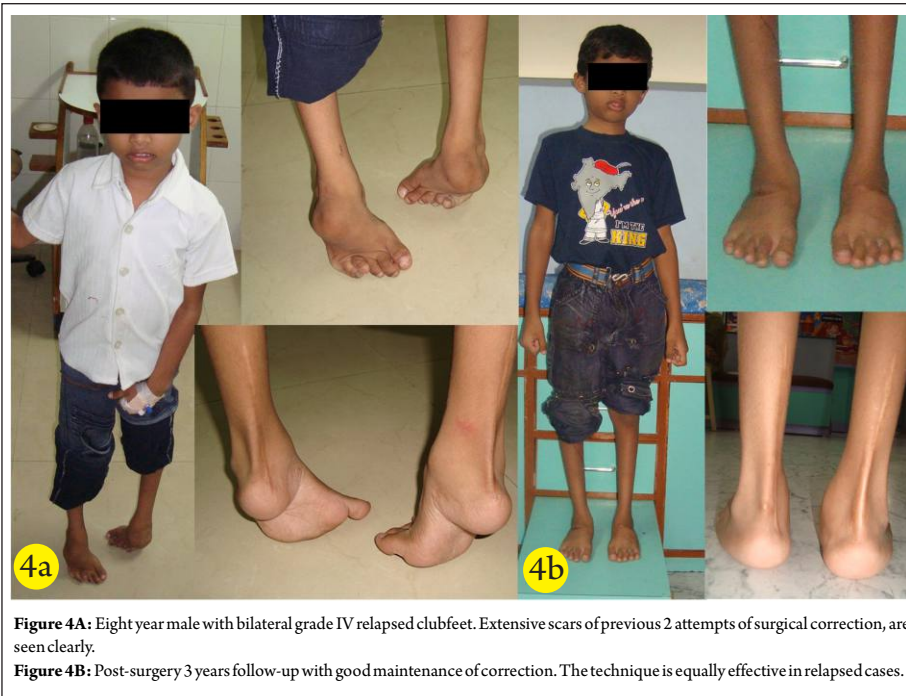

Figure 4A: Eight year male with bilateral grade IV relapsed clubfoot. Extensive scars of previous 2 attempts of surgical correction, are seen clearly.

Figure 4B: Post-surgery 3 years follow-up with good maintenance of correction. The technique is equally effective in relapsed cases.

medially. No iliac crest graft or major implants are required. Fewer follow-ups are required than with other techniques. We believe that the technique is cost effective, requiring only 10% of the cost involved in the Ilizarov or

other techniques. The only disadvantage is possible shortening of foot length in unilateral cases. We observed an average shortening of 1.18cm which is comparable to other series of bony procedures and even

those feet treated [19,20,21] conservatively. We agree that the best approach in developing countries to reduce the load of neglected cases and to avoid long-term problems associated with extensive soft-tissue releases is early [21] intervention during infancy. This can be achieved by seeking help from paramedical persons like nurses or physiotherapists to use the Ponseti technique [21,22] at outlying hospitals, but until that time this load of neglected cases persists; the described technique provides a good alternative procedure to surgeons of the developing world. It is a good alternative to conventional procedures for management of neglected or relapsed, late presenting clubfoot deformities. We do not claim that this is the only best alternative, but it may suit the needs of developing countries, particularly in settings like ours, where patients mostly of low socioeconomic means come from remote villages and are unable to comply in terms of follow-up.

References

- Penny JN. The neglected clubfoot. Techniques in Orthopaedics Vol 20. Philadelphia: Lippincott Williams & Wilkins Inc; 2005: 153–166.
- Kumar PNH, Laing PW, Klenerman L. Medial calcaneal osteotomy for relapsed equinovarus deformity: long term study of the results of Frederick Dwyer. *J Bone Joint Surg.* 1993; 75-B: 967–971.
- Yamamoto H, Muneta T, Ishibashi T, et al. Posteromedial release of congenital club foot in children over five years of age. *J Bone Joint Surg.* 1994; 76-B:555–558.
- Uglow MG, Clarke NMP. Relapse in staged surgery for congenital talipes equinovarus. *J Bone Joint Surg.* 2000; 82-B: 739–743.
- Pell RF, Myerson MS, Schon LC. Clinical outcome after primary triple arthrodesis. *J Bone Joint Surg.* 2000; 82-A:47–57.
- Legaspi J, Li YH, Chow W, et al. Talectomy in patients with recurrent deformity in club foot: a long-term follow-up study. *J Bone Joint Surg.* 2001; 83-B:384–387.
- Lourenco AF, Morcuende JA. Correction of neglected idiopathic club foot by the Ponseti method. *J Bone Joint Surg.* 2007; 89- B:378–381.
- Nogueira MP, Batlle AME, Alves CM. Is it possible to treat recurrent clubfoot with the Ponseti technique after posteromedial release?: a preliminary study. *Clin Orthop Relat Res.* 2009; 467:1298–1305.
- Culverwell AD, Tapping CR. Congenital talipes equinovarus in Papua New Guinea: a difficult yet potentially manageable situation. *Int Orthop.* 2007; 33:521–526.
- Shingade V, Shingade R, Ughade S. Correction of neglected or relapsed clubfoot deformity in an older child by single staged procedure—early results. *Curr. Orthop. Practice.* 2012; 23(2):122–129.
- Shingade V, Shingade R, Ughade S. Single-stage correction for clubfoot associated with myelomeningocele in older children: early results. *Curr. Orthop. Practice.* 2014; 25(1):64–70.
- Dimeglio A, Bensahel H, Souchet P, et al. Classification of clubfoot. *J Pediatr Orthop B.* 1995; 4-B:129–136.
- Bensahel H, Kuo K, Duhaime M. International Clubfoot Study Group Outcome evaluation of the treatment of clubfoot: the international language of clubfoot. *J Pediatr Orthop B.* 2003; 12- B:269–271.
- Wilson HA. Bone operations for the correction of club-foot, based upon an analysis of 435 operations by 108 operators. *J Bone Joint Surg.* 1894; 51-6:159–194.
- Dekel S, Weissman SL. Osteotomy of the calcaneus and concomitant plantar stripping in children with talipes cavovarus. *J Bone Joint Surg.* 1973; 55-B:802–808.
- Tayton K, Thompson P. Relapsing club feet: late results of delayed operation. *J Bone Joint Surg.* 1979; 61-B:474–480.
- Addison A, Fixsen JA, Lloyd-Roberts GC. A review of the Dillwyn Evans type collateral operation in severe club feet. *J Bone Joint Surg.* 1983; 65-B:12–14.
- Graham GP, Dent CM. Dillwyn Evans operation for relapsed club foot: long term results. *J Bone Joint Surg.* 1992; 74-B: 445–448.
- Laaveg SJ, Ponseti IV. Long term results of treatment of club foot. *J Bone Joint Surg.* 1980; 62-A:23–31.
- Wynne-Davies R. Talipes equinovarus: a review of eighty—four cases after completion of treatment. *J Bone Joint Surg.* 1964; 46- B:464–476.
- Dobbs MB, Nunley R, Schoenecker PL. Long-term follow-up of patients with clubfeet treated with extensive soft-tissue release. *J Bone Joint Surg.* 2006; 88-A:986–996.
- Janicki JA, Narayanan UG, Harvey BJ, et al. Comparison of surgeon and physiotherapist-directed Ponseti treatment of idiopathic clubfoot. *J Bone Joint Surg.* 2009; 91-A:1101–1108.

Conflict of Interest: NIL
Source of Support: NIL

How to Cite this Article

Shingade VU. "Dorso-Lateral Wedge correction osteotomy: Is this the way forward?". *International Journal of Paediatric Orthopaedics* Jan-April 2016;2(1):19-22.